[Ricketts/SML Diagnostics] Report
Doctor : Dr. Rob Veis
Patient : Michael Smith Age : 11 years, 8 months Sex : Male Timepoint : Initial

	Value	Norm	Std Dev	Dev Norm	
DENTAL RELATIONSHIPS					
Molar Relation (mm)	0.9	-3.0	1.0	3.9	***
Overjet (mm)	8.0	2.5	2.5	2.2	**
Overbite (mm)	4.1	2.5	2.0	0.8	
Mand Incisor Extrusion (mm)	2.1	1.2	2.0	0.4	
Interincisal Angle (U1-L1) (°)	124.7	130.0	6.0	-0.9	
SKELETAL / DENTAL					
U-Incisor Protrusion (U1-APo) (mm)	9.6	3.5	2.3	2.7	**
L1 Protrusion (L1-APo) (mm)	1.7	1.0	2.3	0.3	
U-Incisor Inclination (U1-APo) (°)	31.5	28.0	4.0	0.9	
L1 to A-Po (°)	23.8	22.0	4.0	0.4	
Occ Plane to FH (°)	9.4	9.1	5.0	0.1	
U6 - PT Vertical (mm)	17.2	14.7	3.0	0.8	
MAXILLO-MANDIBULAR RELATIONSHIPS					
Convexity (A-NPo) (mm)	3.7	1.4	2.0	1.2	*
Mandibular Arc (°)	26.4	28.5	4.0	-0.5	
CRANIOFACIAL RELATION					
FMA (MP-FH) (°)	27.5	25.0	4.5	0.6	
Maxillary Depth (FH-NA) (°)	89.2	90.0	3.0	-0.3	
Facial Axis-Ricketts (NaBa-PtGn)(°)	88.1	90.0	3.5	-0.5	
Facial Angle (FH-NPo) (°)	85.4	87.5	3.0	-0.7	
Facial Taper (°)	67.1	68.0	3.5	-0.3	
DEEP SKELETAL STRUCTURE					
Porion Location (mm)	-45.8	-38.6	2.2	-3.3	**
Cranial Deflection (°)	29.7	27.3	3.0	0.8	
Ramus Position (°)	72.0	76.0	3.0	-1.3	*
Lower Face Height (ANS-Xi-Pm)(°)	46.1	45.0	4.0	0.3	
ESTHETIC					
Lower Lip to E-Plane (mm)	1.7	-2.0	2.0	1.8	*

SUMMARY ANALYSIS
- Class II Molar Relationship
- Skeletal Class II (A-Po)
- Skeletal Class II (ANB)
- Retrusive Mandible (Pg-N)
- Excessive Overjet
- Facial Pattern: Mild Vertical

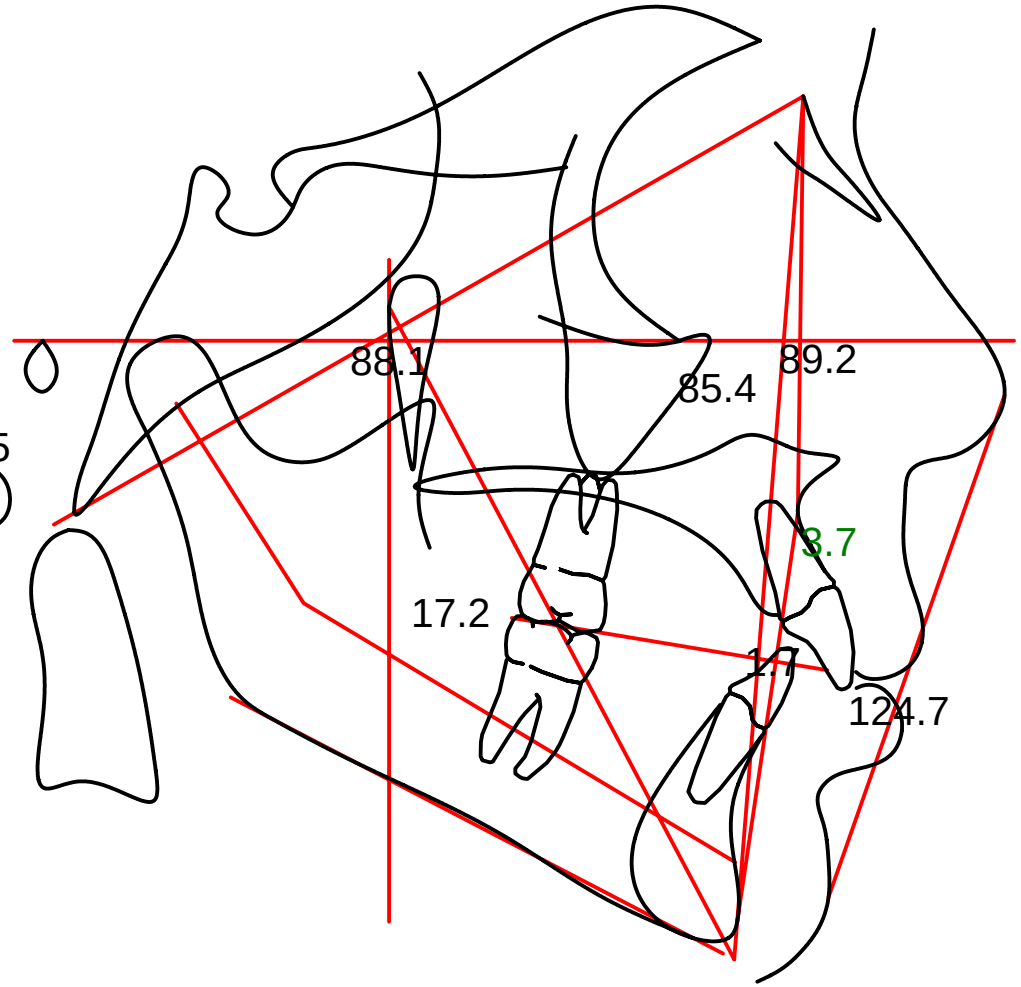

Colors indicate deviations from the norm as follows:
Black: a deviation less than or equal to 1.
Green: a deviation greater than 1 and less than or equal to 2.
Blue: a deviation of greater than 2 and less than or equal to 3.
Red: a deviation of greater than 3.
NOTE: This information is suggestive only. Any diagnosis and prescription should be the decision and sole responsibility of the doctor using this material.